

AMWC  
Monaco  
Special Issue

# PRIME

March 2015  
Volume 5 Issue 2

INTERNATIONAL JOURNAL OF AESTHETIC AND ANTI-AGEING MEDICINE



## COSMECEUTICALS *in clinical practice*

PRP INJECTIONS &  
MICRONEEDLING  
FOR ANDROGENIC ALOPECIA

SKIN BARRIER  
FUNCTION  
WITH SUNCREENS

COMBINATIONAL  
APPROACHES  
FOR FACIAL REJUVENATION

informa

“ A new interest in preventing baldness has been stimulated by cellular therapy with platelet rich plasma (PRP) injected directly into the scalp. ”



# AUTOLOGOUS PRP INJECTION IN ANDROGENIC ALOPECIA

**Gilbert Amgar and Pierre Bouhanna** discuss the use of microneedling along with platelet rich plasma for the treatment of androgenic alopecia

## ABSTRACT

The use of Platelet Rich Plasma (PRP) in cosmetic medicine is now well established and documented. Hair applications became available over the last 8 years. The two main fields of application for PRP are hair

regrowth (androgenic alopecia, alopecia areata) and surgery (to improve hair transplants). Indeed, some of the treatments that exist in this field provide quantifiable results. In this study, the authors conducted an objective evaluation of androgenic alopecia for

over 2 years. The study consisted of 70 patients and each case is documented by digital parameters (hair density, diameter, ratio terminal vellus) and standard photography. Follow-up 3 months after treatment, the authors observed an increase in hair density of

19%, which reached 38% at 12 months. The authors believe it would be suitable to consolidate these results with other evaluations of the same type, carried out by other teams and gradually define the best protocols in order to maximise the results.

**A**NDROGENIC ALOPECIA IS AN extremely common disease that affects both men and women. In normal hair loss, less than one hundred hairs fall each day and are replaced by new thick hair. In the evolution of male and female pattern baldness, the new hair is fine and thin (intermediate hair or miniaturised hair). Male and female baldness usually progresses in a defined pattern.

The most publicised medical treatment available for male pattern baldness is 5% minoxidil lotion and 2% minoxidil for female baldness. Side-effects of minoxidil are minimal but include itching, eczema, and hypertrichosis in females. For male baldness, finasteride taken orally and daily (1 mg) inhibits the 5 $\alpha$  reductase from forming dihydrotestosterone (DHT) and may lead to decreased libido. Spironolactone (in US) appears to be a competitive inhibitor of DHT-receptor binding. Cyproterone acetate (in Europe) can effectively block increased levels of male hormones that cause hair loss in some women.

A new interest in preventing baldness has been

stimulated by cellular therapy with platelet rich plasma (PRP) injected directly into the scalp.

Aiming for better tolerance, an easier process, and high satisfaction rates, researchers and doctors have been looking for improved treatments in this field for a number of years. In this context, PRP takes a prominent place. PRP is defined as an autologous concentrated preparation of platelets and their associated growth factors in a small volume of plasma. The revitalisation qualities of the platelets are well known and have been used for 30 years in various specialties such as plastic surgery, dermatology, rheumatology, and dentistry. The first publication on this subject goes back to 1975<sup>1</sup> and publications of its use on the scalp date back to 2007. PRP eliminates concerns for disease transmission and minimises possible side-effects.

The challenge remains to evaluate the results with objective parameters<sup>2</sup>.

## Epidemiology

The prevalence and severity of pattern hair loss increases with age and the greatest incidence is in Caucasian people. In general, 30% of Caucasian males are affected >



**GILBERT AMGAR, MD**, is Aesthetic Practitioner, France; and **PIERRE BOUHANNA**, is Dermatologist and Expert in Hair Surgery, Paris, France

email: gilbert.amgar@orange.fr

## KEYWORDS

PRP, Platelets Rich Plasma, androgenic alopecia, phototrichogram, Tropicells® kit

▷ by the age of 30, 50% by age 50, and 80% by age 70. In women, 13% of premenopausal women have some evidence of pattern hair loss. However, the incidence increases in women around the time of the menopause and may affect 70% of women over the age of 65 years<sup>3</sup>.

### Physiological consideration

The process begins by performing a blood sample on an anti-coagulated tube with separating gel. The tubes are then centrifuged for a few minutes (speed and time depend on the kit protocol). Owing to their density the red cells fall to the bottom of the tube. On the upper-part of the tube the plasma and the platelets can be found.

Once in the dermal layer, platelets are activated, they inflate and the growth factors are released. Platelet activation is a natural reaction when a traumatic process occurs in tissue (injection or injure). Activation can also be provided by adjunction of CaCl<sub>2</sub> or thrombin. In this series, the authors' did not use any activator. The most important growth factors for hair application are:

- Platelet derived growth factor (PDGF) stimulates the growth of dermal mesenchyme<sup>4</sup>
- Vascular endothelial growth factor (VEGF) creates neoangiogenesis, as well as increases and improves hair growth and hair size<sup>5-8</sup>
- Epidermal growth factor (EGF) stimulates mitosis of epithelial cells and fibroblast, and improves the rate of anagen, the active growth phase of hair follicles<sup>9,10</sup>
- Insulin like growth factor (IGF) slows down apoptosis<sup>11</sup>
- Fibroblast growth factor (FGF) stimulates the proliferation and differentiation of keratinocytes and endothelial cells<sup>12</sup>
- Nerve growth factor (NGF) strongly stimulates hair growth and slows down apoptosis. NGF has a modulating effect on the hair depending on the receptor with which it interacts. NGF also acts as stress-mediators. This is certainly a good way to explain the correlation between stress and hair loss<sup>13</sup>.

**“Epidermal growth factor (EGF) stimulates mitosis of epithelial cells and fibroblast, and improves the rate of anagen, the active growth phase of hair follicles.”**

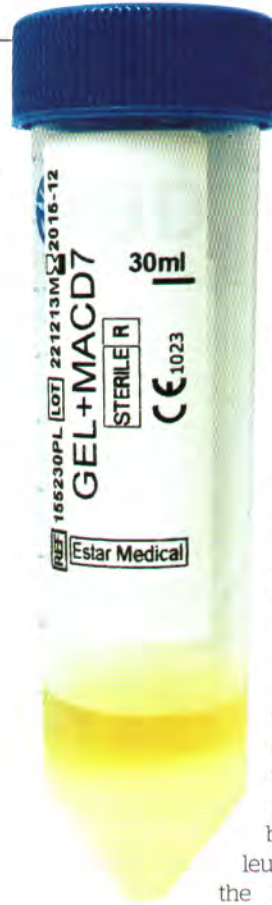### Previous studies

There are three applications in the hair-loss field: androgenic alopecia, alopecia areata, and hair graft. Regarding PRP evaluation in androgenic alopecia, there are five published studies.

The first study from Sorbellini et al<sup>14</sup> exhibited an *in vitro* study conducted on 50 patients. Twelve follicles were taken from each patient, four follicles were induced with PRP, four in Ringer's solution, and four in standard solution. The mitotic activity was then measured. According to the results, the PRP group showed a significant increase of mitotic activity and a reduction of apoptosis.

The purpose of the next study by Takikawa et al<sup>15</sup> was to determine whether there was a difference between simple PRP injections and PRP containing deltaparine

**Figure 1**  
Tropocells®  
PRP kit (Estar  
Medical, Holon,  
Israel)



and protamine microparticles, which acted as carriers for growth factors in the PRP. The study was conducted on 26 volunteers with thin hair who received five local treatments. PRP improved hair density in 16% at 12 weeks. There was no significant difference on the hair density improvement with or without deltaparine.

In the third study, Greco and Brandt<sup>16</sup> demonstrated that infusing growth factors into the scalp did reverse miniaturisation over an 8 month period when compared to control. They observed an increase of 9.7% in average hair shaft diameter at 4 months and then 6.1% at 8 months in the treatment group.

In the fourth study by Sciafone et al, researchers explored the possible clinical benefit of injecting platelet-derived growth factors into the scalp of patients using a specific autologous blood concentrate. Two injections of a leukocyte platelet-rich plasma (L-PRP) with the addition of concentrated plasmatic proteins were administered at baseline and after 3 months in 64 patients. Macrophotographs were taken at baseline and after 6 months, and two independent evaluators rated them using the Jaeschke rating of clinical change. Some improvement was seen in all patients by one evaluator and in 62 by the other<sup>17</sup>.

In the fifth study, Li et al showed that injection of mice with activated PRP induced faster telogen to anagen transition than in control mice<sup>18</sup>.

### Objective of the evaluation


This article intends to retrospectively evaluate a cohort of 70 patients with progressive androgenic alopecia.

These patients underwent a combination therapy with injection of platelet extracts prepared using a PRP kit, and a rotary single-use multipuncture instrument (dermaroller).

### Materials and methods

PRP was prepared using the PRP kit (Tropocells® PRP kit (Estar Medical, Holon, Israel) (Figure 1) through a one step procedure. A total of 30ml of blood was transferred to PRP tubes containing acid-citrate dextrose modified solution (additive/blood ratio of 1:5.67) and separating gel (1:5). Two tubes have been used for each procedure (60cc). The PRP tube

was then centrifuged (1500g for 10 minutes at room temperature) resulting in blood separation into three ▷



**Figure 2**  
Dermaroller

made  
in  
Germany

**HYABELL®** is the new generation of hyaluronic acid dermal fillers with lidocain that is

- immediately visible
- giving natural and long lasting results
- is suitable for various indications in the dermis and subcutis
- reduces pain and enhances patients satisfaction

**More than a promise!**

**HYABELL®**

The soft-tissue filler

**+ LIDOCAINE**

The new range of HYABELL® dermal fillers offers a long lasting improvement and a convincing safety profile. The pre-incorporated lidocaine (0.3%) facilitates the injection procedure and reduces significantly the pain and finally enhances patient's satisfaction.

CE  
0297



Find out more:



**ADODERM GmbH**  
Elisabeth-Selbert-Str. 5  
D-40764 Langenfeld  
Germany  
[www.adoderm.com](http://www.adoderm.com)

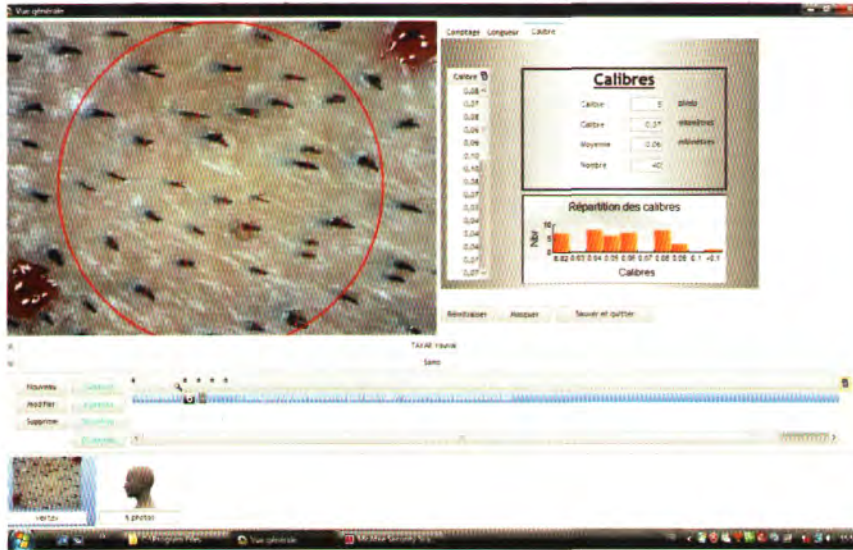


Figure 3 Digital measurement

> layers: an erythrocyte and granulocytes layer at the bottom of the tube beneath the gel, a PRP layer in the middle, and a platelet-poor plasma (PPP) layer at the top of the tube. The PPP layer was drawn out (13±1 ml) and the remaining plasma (5±1 ml) was gently mixed onto the gel surface where 85%±5% of the platelets are present, creating the PRP.

The remaining materials used in this study include:

- A dedicated centrifuge
- A 1.5mm dermaroller, (CE mark, ISO 11137 Medical, and FDA) (Figure 2) designed to make micropunctures on the surface of the scalp
- Digital phototrichogram (Figure 3) with capillary measurement software developed by the authors' team
- Photographs (Figure 4) with six incidences: front, 45°, 90°, 135°, 180°, and side.

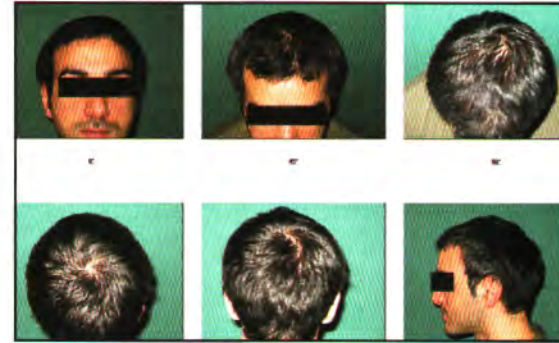

Figure 4 Standard photographs taken from six incidences

“ Following local anaesthesia, the scalp was first traumatised with a 1.5mm microneedling roller and then injected with the PRP. ”

**Inclusion and exclusion criteria**

The inclusion criteria consisted of:

- Men and women
- 20 to 80 years old
- Androgenetic alopecia stages II-VI of the Norwood Hamilton scale, or 1-3 from the Ludwig scale.

The exclusion criteria consisted of:

- History of cancer
- Use of anticoagulants or blood products
- Scalp active skin infection
- Haematological diseases
- Pregnancy.

**Methodology**

Seventy patients (31 males and 39 females) were recruited for the study. Digital measurements (tattoo mark, hair density, diameter, and ratio) and standard photograph were taken from each participant. In all, 60cc of blood was drawn and 10cc of PRP was processed. Following local anaesthesia, the scalp was first traumatised with a 1.5mm microneedling roller and then injected with the PRP. Patients underwent two sessions 3 months apart. No external activation has been provided.

**Schedule**

Before the procedure could take place, a prior consultation with haematologic analysis and informed consent was required.

**First treatment on day 0**

- Signature of informed consent
- Photographs taken from six different angles
- Digital phototrichogram for measurement of capillary density and the diameter of the hair in an area identified by two micro-tattoos
- Local anaesthesia, application of the dermaroller and injection of PRP.

**Second treatment on day 90**

- Photographs taken again from the same six angles

**Table 1 Descriptive statistics for the samples**

**NORMALITY TEST**

**AGE**

Seventy patients from 17 to 77 years old. The sex ratio is 39 women to 31 men.

	N	Mean	EcTyp	Chi²	Chi² Lim	Proba	Normality
Age	70	44.7	14.31	9.443	11.07	<0.093	<b>ACCEPT</b>

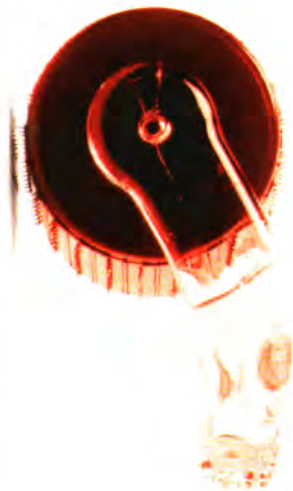**DENSITY**

	N	Mean	EcTyp	Chi²	Chi² Lim	Proba	Normality
Density	70	151.3	47.25	3.494	7.815	<0.32	<b>ACCEPT</b>

**CALIBER**

	N	Mean	EcTyp	Chi²	Chi² Lim	Proba	Normality
Caliber	70	48.29	11.17	6.288	11.07	<0.28	<b>ACCEPT</b>

The above analysis demonstrated that the size of the groups chosen is acceptable and can statistically represent the population, as tested by chi² test.



- Digital phototrichogram
- A search for side-effects
- Local anaesthesia, application of the dermaroller, and injection of PRP.

**Examination on day 180, 270, and 360**

- Photographs taken again from the same six angles
- Digital phototrichogram
- A search for side-effects.

**Treatment with PRP and dermaroller**

First, a local anaesthesia injection of 1% lidocaine must be given prior to use of the dermaroller or intradermal injections of PRP.

In order to allow better diffusion of the PRP, multiple perforations were conducted on scalp areas affected by the process of androgenic alopecia using a single-use dermaroller instrument with peaks of 1.5 mm.

Next, treatment with PRP involves the injection of 10 cc of PRP obtained by centrifugation of the PRP kit with the centrifuge pre-programmed for this purpose. The injections will cover the area of the affected scalp. The preparation of the PRP was made in accordance with the operating instructions of the kit manufacturer.

**Review of side effects**

Common side-effects associated with PRP injections and dermaroller include the following:

- Pain
- Redness
- Pruritus
- Oedema
- Haematoma
- Other.

**Results at 3 months**

**Density**

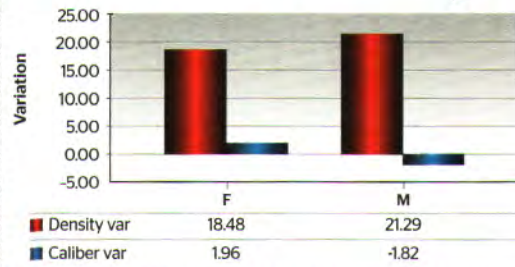
At day 90, the authors observed an improvement of 19.7% in hair density, which they believed to be a very interesting result coming 3 months after the first session. The patients reported no more hair loss after 2 or 3 weeks after their first session. However, an initial acceleration of the fall due to the telogen expulsion was observed in some patients.

The repartition of the improvement was found to be very close between terminal and vellus hair (terminal +30.8% and vellus +28.3%). Hairs are considered as vellus if the diameter is <40 microns.

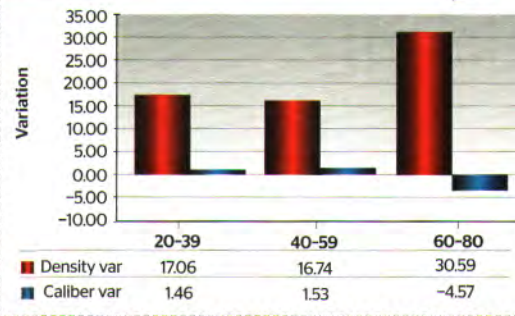
The percentage of improvement is defined as: (density at 3 months minus initial density) divided by initial density. It is not the number of new hairs.

Regarding sex, (Figure 5) the authors observed a small advantage for the men in density variation (21.3% against 8.5% for the women).

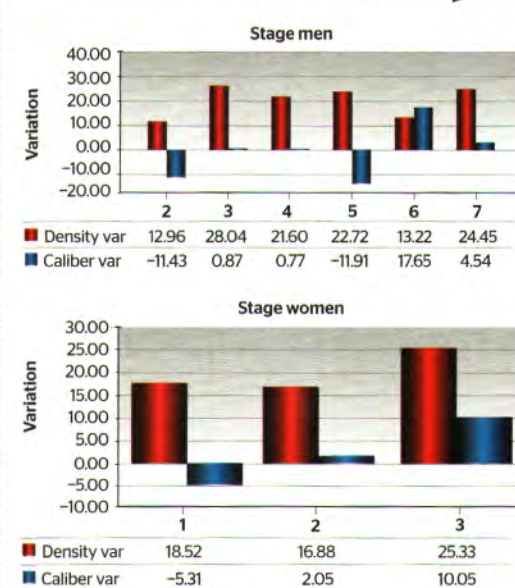
**Figure 5** Density and diameter variation at 3 months regarding sex



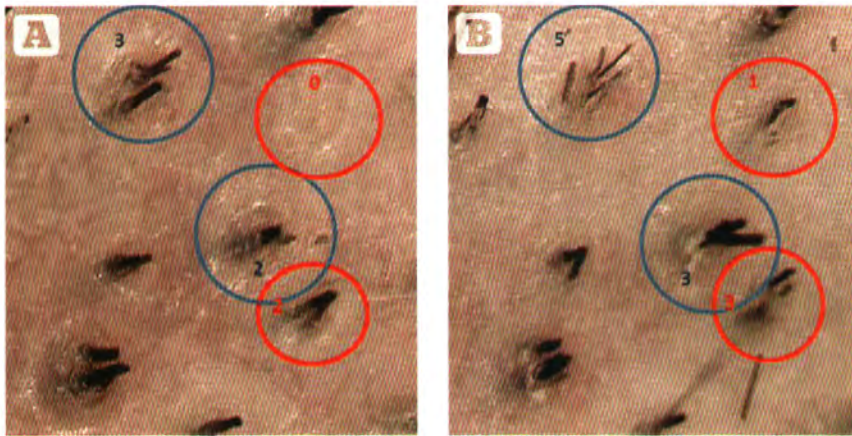
**Figure 6** Density and diameter variation at 3 months regarding age



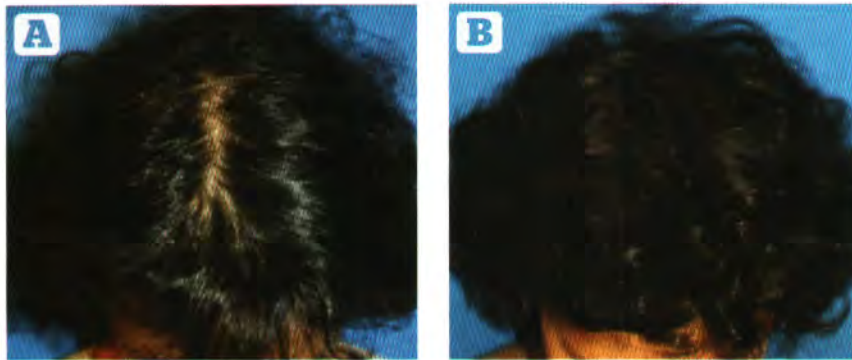
**Figure 7** Density and diameter variation at 3 months regarding stage



**“ At day 90, the authors observed an improvement of 19.7% in hair density, which they believed to be a very interesting result coming 3 months after the first session. ”**



**Figure 8** (A) digital image taken on day 1, and (B) at the same place on day 90 showing the change in hair density



**Figure 9** (A) Before, and (B) 3 months after one PRP session

▷ Regarding age, better results on density change were witnessed in patients over the age of 60 (30.6% against 17% for those under 60 years of age) (Figure 6).

Regarding stage, results were not as responsive for men in stages II and VI of the Norwood-Hamilton scale (Figure 7). Statistically, a clear correlation cannot be established between the results and the stages of hair loss for men. On the other hand, the female group showed higher values on stage 3 (25.3%) vs stages 1 and 2 (17%).

**Diameter**

At day 90, the mean diameter does not change (+0.3%). Regarding sex, the authors observe a little advantage for the women (+1.96% against -1.82% for the men).

Regarding age, results are not so positive on diameter after 60 years (-4%). It seems that there is a correlation between hair density and the growth of new thin hair, so the mean diameter decreases.

Regarding stage, the authors could not establish a

correlation regarding the stage for men. For women, they clearly observe a correlation on stage (stage 1: -5.31%, stage 2: +2.05%, and stage 3: +10.05%).

**Telogen/vellus ratio**

The results concerning the ratio are comparable with the diameter evolution.

Over the 90 day period, the authors observed many differences as illustrated by the digital hair image in Figure 8. As can be observed in Figure 8, the two images were taken exactly in the same place. The highlighted area shows the variation in hair density, which is changing from 3 to 5, 0 to 1, 2 to 3, and 2 to 3. This is a very important result that confirms clearly the effect of PRF on density.

The results can be seen in the macrophotographs before and 3 months after one PRP session (Figure 9).

**Results at 12 months**

Following 12 months from the first treatment, only 46 patients (out of the initial 70) were still involved in the study due to several causes:

- Distance (7): The PRP procedure is not often used,

**“ At 12 months, after two sessions of PRP, an improvement of 38% in density variation was observed. This is a very important evolution. ”**

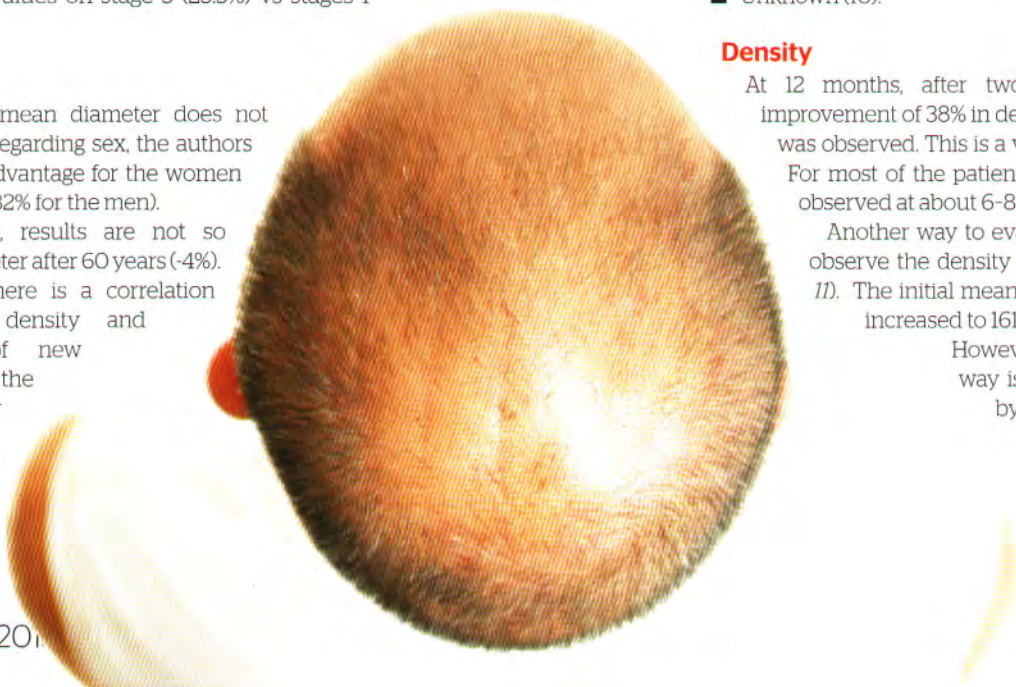
- so recruitment is not local but rather national or international. This explains the monitoring difficulties
- Pain (2): This is not a painless procedure and pain evaluation is between 2 and 5 on a 10 point scale
- Loss of tattoo (1): Despite a standardised technique, sometimes the skin does not keep the pigment.
- Not enough of a result and the patient did not return (4)
- Unknown (10).

**Density**

At 12 months, after two sessions of PRP, an improvement of 38% in density variation (Figure 10) was observed. This is a very important evolution. For most of the patients, the improvement was observed at about 6-8 months.

Another way to evaluate the evolution is to observe the density in absolute value (Figure 11). The initial mean was 128 hairs/cm<sup>2</sup> and it increased to 161/cm<sup>2</sup> at 12 months.

However, the more accurate way is to evaluate the result is by using base 100 (Figure 12). This formula is often used in financial statistics to evaluate the yield of an investment. Values





are converted as if every patient had an initial density at 100 hairs/cm<sup>2</sup>. In this study, we obtained the following values: 100 - 115 - 122 - 121 - 123.

Looking at *Figure 12*, the yield is 23% and it seems to be a good reflection of the clinical reality. Looking at the curve, it is not linear as you would expect with the density variation. The curve has a logarithmic aspect and has a progression stage (6 months) and then a stabilisation stage. This is the translation of the physiological function. The procedure does not create new follicles. If it was so, a linear curve should be evident. Instead, the procedure stimulates a lot of follicles that are not strong enough to provide hair but are not yet dead.

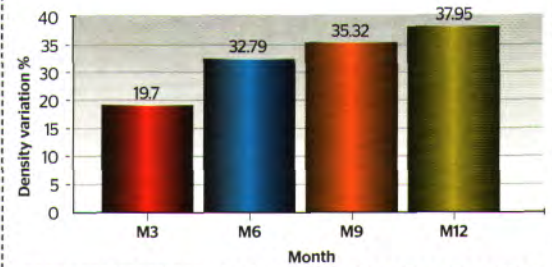
'New' hair grows but not new follicles. Usually, one session every year seems to be enough to keep the benefit. In a few cases, when a decrease is observed at 9 months, the authors provide two sessions every year.

The result can be seen on the macrophotographs before and 12 months after two PRP sessions (*Figures 13-14*).

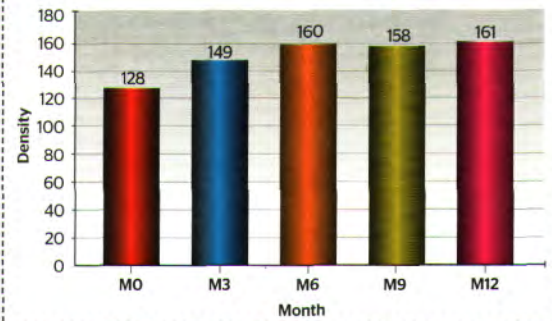
Regarding sex, at 3 months women witnessed a slight delay. At 12 months, they recovered a clear advantage with 44% improvement (only 31% for the men) (*Figure 15*). ▷

**“The procedure does not create new follicles, instead, the procedure stimulates a lot of follicles that are not strong enough to provide hair but are not yet dead.”**

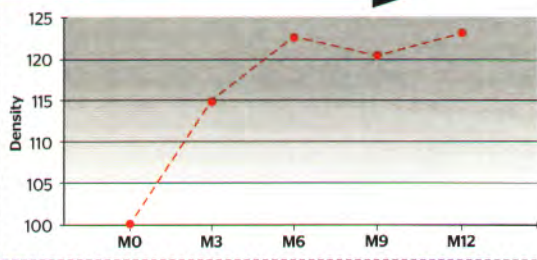
**Figure 10** Density variation over 12 months



**Figure 11** Density over 12 months looking at absolute value



**Figure 12** Density over 12 months using the base 100 model



▷ Regarding age, better results were recorded for density after 60 years of age. (74% against 33% between 40 and 60 and 25% under 40 years of age) (Figure 16).

Again regarding stage, the authors could not establish a correlation regarding the stage for men. For women, the authors clearly observed a correlation on stage 1: 15.35%, stage 2: 28.78%, and stage 3: 129.39% (Figure 17).

**Diameter**

Globally, no significant changes were observed. However, focusing on women in stage 3, the authors observed a very positive evolution stage 1: -14%, stage 2: -1%, and stage 3: +36%.

The authors looked to see if there was a correlation between improvement and initial value. No statistically valid correlation with linear regression for either men or women was found.

**Side-effects**

Pain is always present (from 2 to 5 on a 10 point scale). It is not a painless procedure and it could be useful to use analgesic gas. For one patient a preauricular lymph node



occurred on the second day and disappeared spontaneously 2 days later.

**Limit of this evaluation**

It is impossible to take measurements all over the scalp. Therefore, the authors had to choose an evaluative area to see the changes brought about by the procedure. Nevertheless, the results can be different between areas. For example, an 18% improvement was observed on the border line for a man in stage 5, while no changes were detected on the vertex area.

Using adhesive also posed an issue. Before taking the digital phototrichogram, the authors cut the hair very short and used an adhesive tissue to take away hair fragments in order to get a clear picture. The hypothesis cannot be excluded that some telogen hair was present in the area and was subsequently removed.

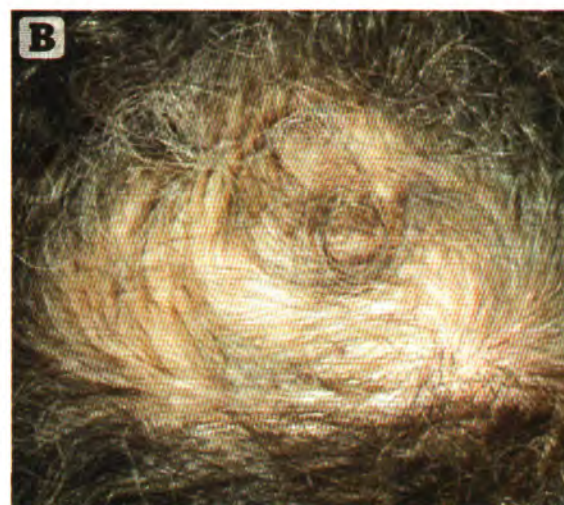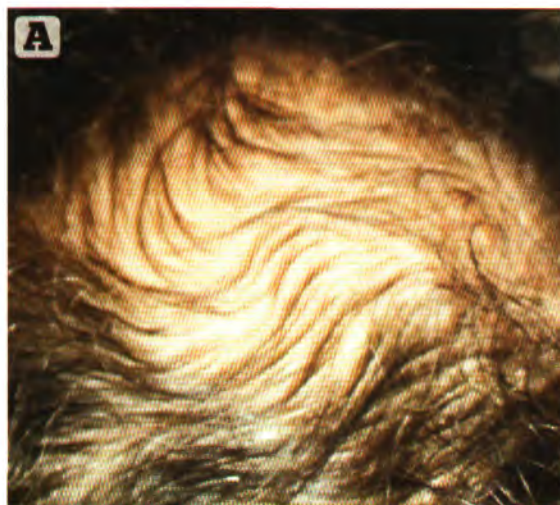The authors' protocol used two therapeutic parameters: PRP and microneedling. Even if clinical experience shows that the most important effect is due to the PRP, this evaluation is unable to prove it. The goal was to get the best result for the patient and the authors are evaluating other studies with different protocols (without microneedling, with activation, and with less quantity) and will soon be able to quantify the result and improve the protocol.

The number of patients who dropped out of the study before the 12 month follow-up was high but this is not a prospective study, this is a retrospective evaluation.

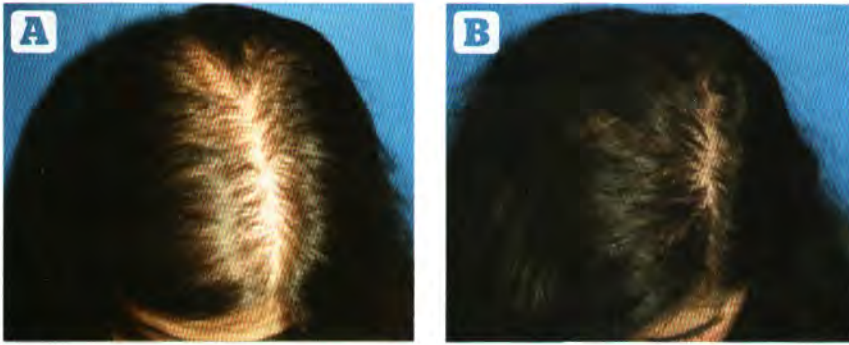
**Conclusion**

In conclusion, the authors evaluated 70 cases of androgenic alopecia over a period of 3 months, and 46 ▷

“The authors looked to see if there was a correlation between improvement and initial value [on diameter]. No statistically valid correlation with linear regression for either men or women was found.”



**Figure 13** (A) Before and (B) 12 months after two PRP sessions



▷ cases over 12 months post-treatment with PRP. They observed an improvement of 19.7% for the density variation at 3 months that reached 38% at 12 months. The aspect of the curve suggests that new follicles were not being produced, and the authors believe that PRP treatment stimulates many live follicles that are not strong enough to provide hair. Therefore, 'new' hair is observed, but not new follicles.

**“The goal was to get the best result for the patient and the authors are evaluating other studies with different protocols and will soon be able to quantify the result and improve the protocol.”**

Globally, concerning the diameter, no significant changes, except for advancing age (60-80 years) and women in stage 3, were observed.

It would be useful to consolidate these results with other evaluations of the same type, provided by other teams and gradually define the best protocols for the best results.

► **Declaration of interest** None

► **Figures 1-17** © Gilbert Amgar and Pierre Bouhanna

**Figure 14** (A) Before and (B) 12 months after two PRP sessions

**Key points**

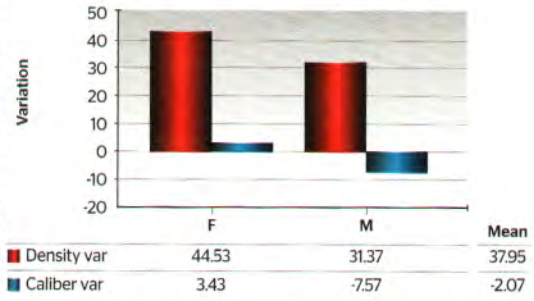
1 This article intended to retrospectively evaluate a cohort of 70 patients with progressive androgenic alopecia

2 These patients underwent a combination therapy with injection of platelet extracts (without any activation) and a rotary single-use multipuncture instrument. Digital measurements (tattoo mark, hair density, calibre, and ratio) and standard photographs were taken from each participant

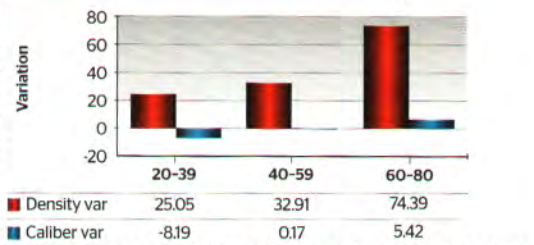
3 An improvement of 19.7% for the density variation at 3 months, reaching 38% at 12 months was observed

4 Concerning the calibre, no significant changes, except for advancing age (60-80 years) and women in stage 3 were observed

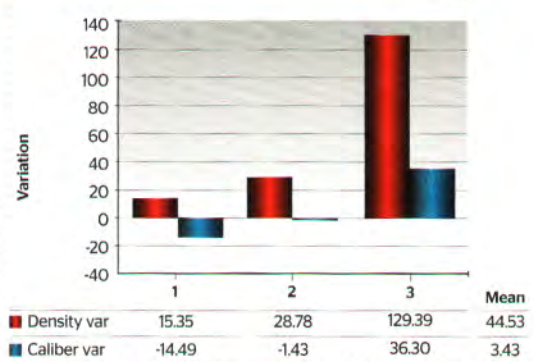
**Figure 15** Density and diameter variation at 12 months regarding sex



**Figure 16** Density and diameter variation at 12 months regarding age



**Figure 17** Density and diameter variation at 12 months regarding stage for women



**References**

- Rosenthal A, Harbury C, Egbert P, Rubenstein E. Use of a platelet-fibrinogen-thrombin mixture as a corneal adhesive: experiments with sutureless lamellar keratoplasty in the rabbit. *Invest Ophthalmol* 1975;14(11): 872-5
- Bouhanna P. Different methods of evaluation—object assessment of hair loss and alopecia. *Praxis*, 1997; 86(23): 1000-1003
- Hoffmann R, Happle R. Current understanding of androgenetic alopecia. Part II: clinical aspects and treatment. *Eur J Dermatol* 2000; 10(5): 410-7
- Takakura N, Yoshida H, Kunisada T, Nishikawa S, Nishikawa S. Involvement of Platelet Derived Growth Factor Receptor-alpha in Hair Canal Formation. *J Invest Dermatol* 1996; 107(5): 770-777
- Yano K, Brown L, Detmar M. Control of hair growth and follicle size by VEGF-mediated angiogenesis. *J Clin Invest* 2001, 107(4): 409-417
- Rinaldi F, Sorbellini E, Bezzola P. The role of up-stimulation of growth factors in hair transplantation: improve the revascularization of transplanted hair growth mediated by angiogenesis. *Forum* 2007; 2
- Sharov A, Tobin DJ, Sharova TJ, et al. Changes in different melanocyte populations during hair follicle involution. *J Invest Dermatol*, 2005; 125: 1259-1267
- Li M, Marubayashi A, Nakaya Y, et al. Minoxidil-induced hair growth is mediated by adenosine in cultured dermal papilla cells: possible involvement of sulfonyleurea receptor 2B as a target of Minoxidil. *J Invest Dermatol* 2001; 117(6): 1594-1600
- Mak KK, Chan SY. Epidermal growth factor as a biologic switch in hair growth cycle. *J Biol Chem* 2003; 278(28): 26120-6
- Rosenquist TA, Martin GR. Fibroblast growth factor signalling in the hair growth cycle: expression of the fibroblast-growth factor receptor and ligand genes in the murine hair follicle. *Dev Din* 1996; 205(4): 379-386
- Weger N, Schlake T. IGF-1 signalling controls the hair growth cycle and the differentiation of hair shafts. *J Invest Dermatol* 2005; 125(5): 873-882
- Mak KK. A transgenic mouse model to study the role of epidermal growth factor (EGF) in hair and skin development. University of Hong Kong, 2002. Available at: [http://dx.doi.org/10.5353/th\\_b4257678](http://dx.doi.org/10.5353/th_b4257678) [last accessed February 4 2015]
- Peters EMJ, Paus R, Klapp BF, Arck PC. L6 neuroimmunological hair growth control is stress-sensitive: an old paradigm revisited. Conference abstracts, Zurich European Hair Research Society, 2005. Available at: <http://www.ehrs.org/conferenceabstracts/2005zurich/guestlectures/L6-peters.htm> [last accessed February 4 2015]
- Sorbellini E, Trink A, Rinaldi F. Experimental clinical assessment of the use of platelet-rich plasma in dermatology and rationale for its use in the treatment of non-scarring alopecia. *La Medicina Estetica* 2011; 35 (4)
- Takikawa M, Nakamura S, Nakamura S, et al. Enhanced Effect of Platelet-Rich Plasma Containing a New Carrier on Hair Growth. *Dermatol Surg* 2011; 37(12): 1721-9
- J Greco, R Brandt. The effects of autologous platelet rich plasma and various growth factors on non-transplanted miniaturized hair. *Hair Transplant Forum International* 2009; 19(2): 49-50
- Scavone G, Raskovic D, Greco J, Abeni D. Platelet-Rich Plasma for androgenic alopecia: a pilot study. *Dermatol Surg* 2014; 40(9): 1010-9
- Li ZJ, Choi HI, Choi DK. Autologous platelet rich plasma: A potential Therapeutic Tool for Promoting Hair Growth. *Dermatol Surg* 2012; 38(7 Pt 1): 1040-6